



**PATIENT PRESENTING CLINICAL SIGNS**

Pancake Gooding

History: Anorexia past 3 days, lethargic, possibly polydipsic, vomiting.

**SPECIES**

Physical Examination: Dehydration, grade 2/6 systolic murmur, abdominal discomfort.

Feline

Urinalysis: N/A.

**BREED**

Himalayan

CBC: Left shift neutrophilia.

Serum Biochemistry: Hyperglycemia, elevated SDMA, globulins, lipase. Hypokalemia. Abnormal fPL.

Radiographic Findings: N/A.

**SEX**

MN

**AGE**

10 years

**WEIGHT**

5.5 kg

**ULTRASONOGRAPHIC EXAMINATION OF THE ABDOMEN**

**Urinary System**

Full urinary bladder with a normal thickness and appearance of the wall. Normal anechoic urine with no sediment or uroliths evident.

Normal trigone area, proximal urethra, and iliac blood vessels.

Normal iliac lymph nodes. Ureters not visualized.

Normal renal size (left 4.8, right 4.6 cm) with increased echogenic appearance, some loss of cortico-medullary differentiation, and normal capsule, pelvis, and blood flow.

**Reproductive System**

N/A.

**Adrenal Glands**

Normal shape, echogenic appearance, size, and position. Right 0.88 x 0.3/0.32 cm.

**Spleen**

Normal size (1 cm) with a diffuse increased echogenic-faint nodular appearance. Smooth homogenous parenchyma, smooth curvi-linear capsule, and normal vasculature. No evidence of inflammatory, neoplastic, infarction, or infiltrative changes noted. Incidental myelolipomas.

**Liver**

Normal size, with a diffuse increased echogenic appearance, and some loss of portal markings. No nodules or masses evident. Full gall bladder containing normal anechoic bile. Normal thickness and echogenic appearance of the gall bladder wall. Normal bile duct (0.27 cm).

**Gastrointestinal**

Normal appearance of the pylorus, stomach, duodenum, small intestine, ileo-cecal junction, and colon with normal thickness (duodenum 27 cm, jejunum 0.22 cm, colon 0.15 cm), layering and peristaltic activity.

**INTERPRETED BY**

Remo Lobetti, BVSc,  
MMedVet (Med), PhD,  
Dipl. ECVIM

**IMAGING PERFORMED BY**

Dr Alastair Westcott,  
DVM

**HOSPITAL NAME**

**REFERRING VET**

Dr Alastair Westcott,  
DVM

**INVOICE**

302551

**DATE**

9/8/21



**PATIENT** *Pancreas*

Pancake Gooding Enlarged (both lobes 0.8 cm) with a hypoechogenic and irregular appearance. Irregular capsule. Visible pancreatic duct (0.2 cm), Hyperechogenic appearance of the mesentery and fat surrounding the pancreas.

**SPECIES**

Feline *Free Abdomen*

**BREED**

Himalayan No mesenteric lymphadenomegaly.

No ascites.

**SEX**

**ULTRASONOGRAPHIC FINDINGS**

MN

Primary Findings:

**AGE**

10 years

- Pancreatitis.
- Hepatopathy.
- Splenic pathology.

**WEIGHT**

5.5 kg

Secondary Findings:

- Age-related renal changes.

**INTERPRETED BY**

Remo Lobetti, BVSc,  
MMedVet (Med), PhD,  
Dipl. ECVIM

**INTERPRETATION OF THE FINDINGS & FURTHER RECOMMENDATIONS**

The appearance of the pancreas is typical for pancreatitis.

Etiologies for the hepatopathy would be secondary to the pancreatitis, reactive, cholangio-hepatitis complex, lipidosis, granulomatous disease, and infiltrative neoplasia.

Etiologies for the splenic pathology would be reactive, hyperplasia, splenitis, and neoplasia.

Further assessment would be FNA cytology of the liver and spleen.

Specific therapy would be dependent on an etiological diagnosis. Symptomatic management of would be fluid therapy, correction of the hypokalemia, analgesics (opioids, NSAIDs), anti-emetics (metoclopramide), gastric protectants (sucralfate, omeprazole), and a low-fat intestinal diet.

**IMAGING PERFORMED BY**

Dr Alastair Westcott,  
DVM

**HOSPITAL NAME**

**REFERRING VET**

Dr Alastair Westcott,  
DVM

**INVOICE**

302551

**DATE**

9/8/21



**PATIENT**

Pancake Gooding

**SPECIES**

Feline

**BREED**

Himalayan

**SEX**

MN

**AGE**

10 years

**WEIGHT**

5.5 kg

**INTERPRETED BY**

Remo Lobetti, BVSc,  
MMedVet (Med), PhD,  
Dipl. ECVIM

**IMAGING PERFORMED BY**

Dr Alastair Westcott,  
DVM

**HOSPITAL NAME**

**REFERRING VET**

Dr Alastair Westcott,  
DVM

**INVOICE**

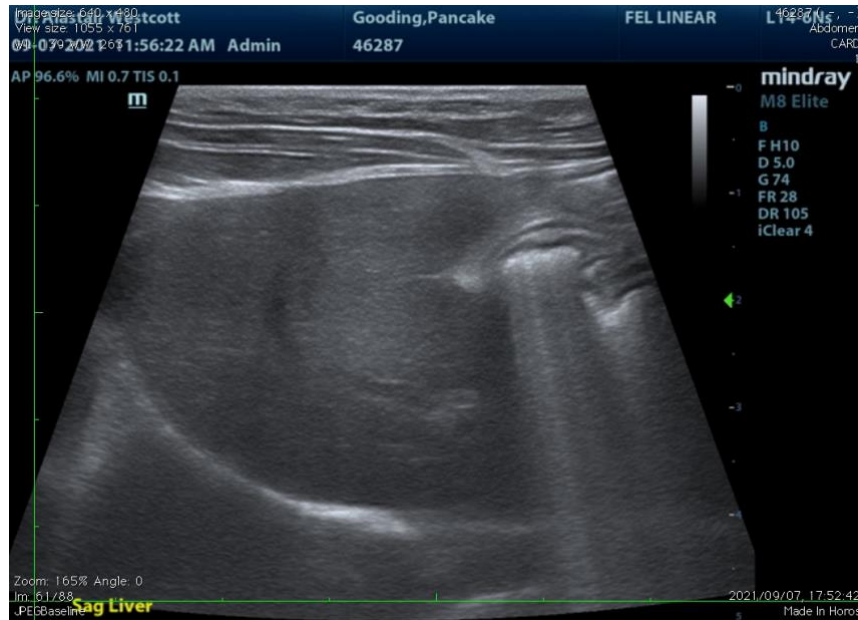
302551

**DATE**

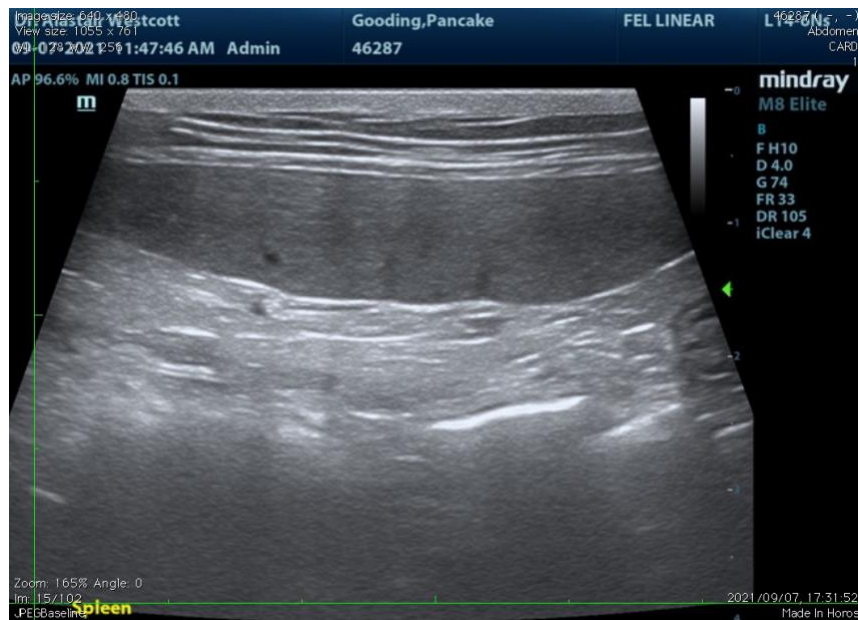9/8/21

**IMAGES**

**Liver**



**Spleen**





**PATIENT Pancreas**

Pancake Gooding

**SPECIES**

Feline

**BREED**

Himalayan

**SEX**

MN

**AGE**

10 years

**WEIGHT**

5.5 kg

**INTERPRETED BY**

Remo Lobetti, BVSc,  
MMedVet (Med), PhD,  
Dipl. ECVIM

**IMAGING PERFORMED BY**

Dr Alastair Westcott,  
DVM

**HOSPITAL NAME**

**REFERRING VET**

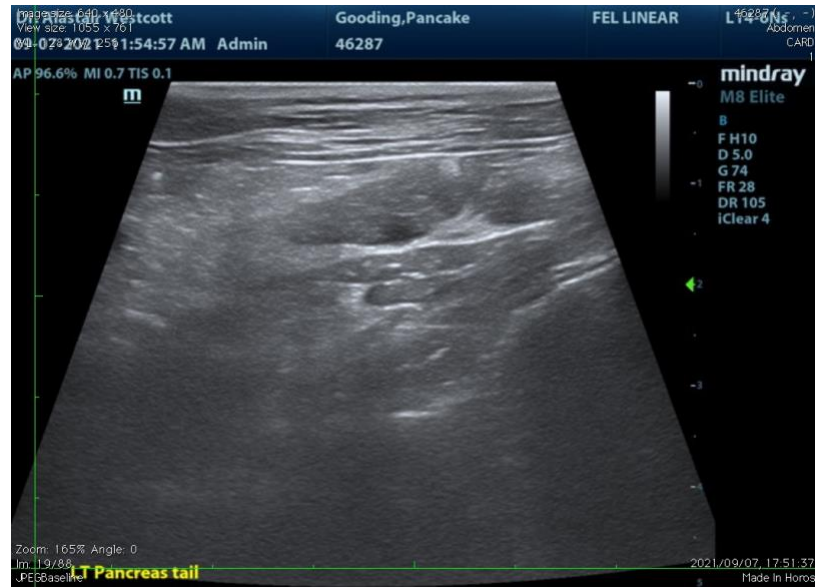
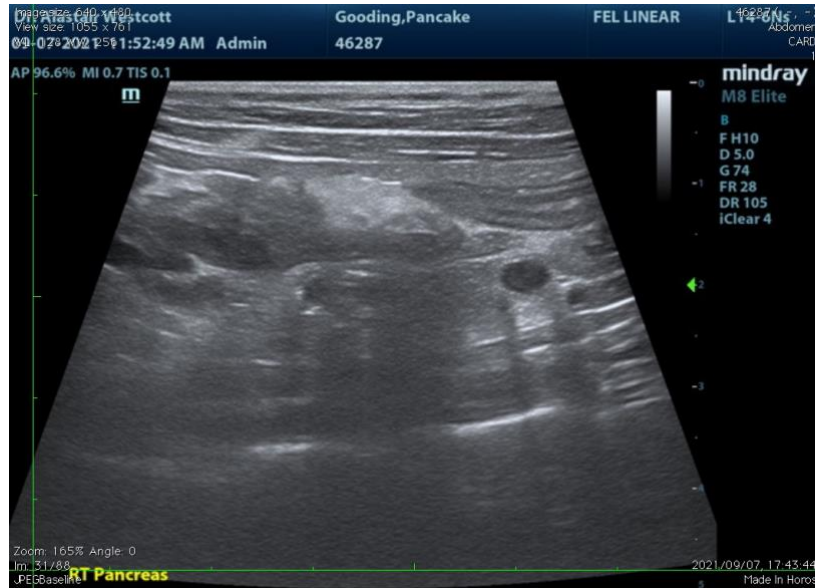
Dr Alastair Westcott,  
DVM

**INVOICE**

302551

**DATE**

9/8/21



The information and recommendations provided are based on the images presented by the referring veterinarian. No evaluation can be communicated regarding pathology that was not visible in the image/video clips provided.

Thank you for this referral. If the clinical or image interpretation does not parallel your findings or if I can be of any further assistance, please contact me.

**Remo Lobetti, BVSc, MMedVet (Med), PhD, Dipl. ECVIM (Internal Medicine)**  
[rlobetti@mweb.co.za](mailto:rlobetti@mweb.co.za)